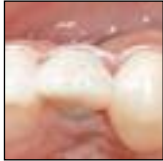



## Considerations of Implant Abutment and Crown Contour: Critical Contour and Subcritical Contour



Huan Su, DDS\*  
 Oscar González-Martín, DDS\*\*  
 Arnold Weisgold, DDS\*\*\*  
 Ernesto Lee, DMD\*\*\*\*

*Adequately contoured implant restorations need to transition from the circumferential design of the implant head to the correct cervical tooth anatomy. The implant abutment may be used to effect this transition provided there is sufficient running room. Implant restorations have been described as overcontoured, flat, and undercontoured. It has been shown that overcontouring will generally cause apical positioning of the gingival margin, while undercontouring will induce the opposite effect. However, these terms have been applied arbitrarily and without allocating specific determinants. Furthermore, the concept of "contour" as originally adapted from tooth-supported restorations needs to be redefined as it pertains to implant dentistry. Two distinct zones within the implant abutment and crown are defined as critical contour and subcritical contour. Any alteration of critical or subcritical contour can modify the soft tissue profile. The purpose of this paper is to determine the effect of abutment contour modifications at these zones on the peri-implant soft tissues, including the gingival margin level, papillae height, gingival architecture, labial alveolar profile, and gingiva color. (Int J Periodontics Restorative Dent 2010;30:335–343.)*

\*Private Practice, Tacoma, Washington.

\*\*Adjunct Assistant Professor, Periodontics and Periodontal Prosthesis Program, School of Dental Medicine, University of Pennsylvania, Philadelphia, Pennsylvania.

\*\*\*Adjunct Professor of Periodontics and Former Director, Periodontal Prosthesis Program, School of Dental Medicine, University of Pennsylvania, Philadelphia, Pennsylvania.

\*\*\*\*Clinical Professor of Periodontics and Director, Periodontal Prosthesis Program, School of Dental Medicine, University of Pennsylvania, Philadelphia, Pennsylvania.

Correspondence to: Dr Huan Su, 2302 South Union Avenue, C-22, Tacoma, Washington 98056; email: suhuan@gmail.com.

To achieve an optimal esthetic implant restoration, the correct implant placement into an adequately prepared site is critical. Several publications have advocated approaching ideal implant placement from a three-dimensional perspective. Some of the recommended parameters include: (1) apicocoronal: the implant position should be 2 to 4 mm apical to the expected gingival margin position; (2) faciolingual: 2 mm of facial bone is recommended to prevent the loss of facial tissue, and the implant should be positioned slightly palatal to the incisal edge; and (3) mesiodistal: the implant should be 2 mm away from adjacent teeth, and a 3-mm space between implants is recommended.<sup>1–8</sup> Ideally, the implant abutment should mimic a full crown preparation. Use of a customized abutment in cases of anterior implants has been a successful practice for a number of years. The importance of transitioning from a circumferential implant neck to a proper cervical anatomy has been emphasized to create a natural-looking implant-supported restoration.<sup>7</sup> Bichacho and Landsberg<sup>9</sup> emphasized the use of a cervical contouring concept utilizing

a customized provisional restoration to reshape the soft tissue around implants. Others advocate the use of a transitional custom abutment, which is subsequently picked up with an open tray impression technique to accurately transfer the prosthetically developed peri-implant contours and ensure that the definitive abutment is a precise replica of the customized provisional abutment.<sup>10</sup>

The actual contour of the implant abutment, however, has not been well defined. It has been demonstrated that in tooth-supported restorations, overcontouring will cause apical migration of the gingival margin while undercontouring will induce coronal positioning of gingival margin.<sup>7,11</sup> Generally, the terms "overcontour" and "undercontour" of the implant crown are used arbitrarily, lacking quantifying determinants or specific descriptions with respect to location of the contour modifications. Since the concept of contour is adapted originally from tooth-supported restorations, there is a need to redefine the concept of contour in implant dentistry.

### **Implant abutment-crown contour**

It has been the authors' observation that the response of the peri-implant gingival tissues to abutment-crown contour modifications will vary depending on the location of the contour change. Based on the tissue response, two general areas have been identified. The first is termed *critical contour*, which is the area of the implant abutment and crown located

immediately apical to the gingival margin. It follows the 360-degree circumference of the restoration and was found to be significant within a 1-mm range apicocoronally (Fig 1). These are preliminary observations, however, and the exact dimension has yet to be determined. In a cement-retained implant restoration, the critical contour may be on the crown, abutment, or both depending on the location of the finish line.

The facial profile of the critical contour is important in determining the zenith and labial gingival margin level, which has an impact on the clinical crown length of the restoration. It may also be possible to control the location of the gingival zenith through modifications of the critical contour. The convexity of the facial critical contour has an effect on the gingival margin scallop. The interproximal critical contour determines whether the implant crown will exhibit a triangular or square shape. The location of the critical contour is dynamic depending on the gingival margin position and may change in instances such as recession. Clinically, the design of the critical contour around all aspects of the restoration should correlate to the desired anatomy and gingival architecture of the implant-supported crown.

The second area has been termed *subcritical contour* and is located apical to the critical contour, provided that sufficient "running room" is present. Running room is defined as the distance from the implant neck to the gingival margin, thus allowing for the establishment of the proper cervical contour of the artificial restoration. The alteration of the subcritical contour

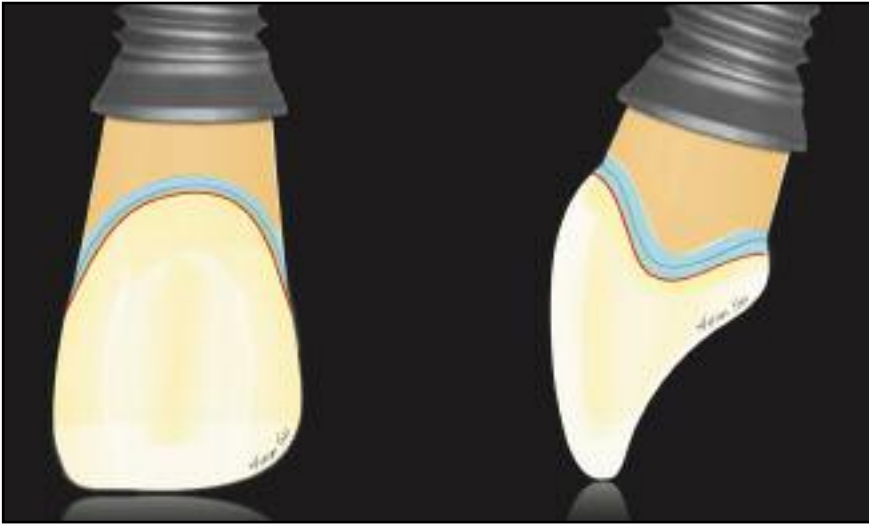
within a physiologic range should not affect the gingival margin level in a clinically significant manner. However, if implant placement is too shallow, this contour will not exist. The subcritical contour may be designed as a convex, flat, or concave surface (Fig 2). Modifications in the facial or interproximal subcritical contour elicit different responses from the peri-implant tissue as well.

Alterations of both critical and subcritical contour can be used to enhance peri-implant soft tissue esthetics. However, in certain situations where changing the shape of the implant crown is not desirable, the critical contour should not be altered. Only modification of the subcritical contour allows for a more favorable esthetic outcome through enhancement of the soft tissue profile without altering the shape of the implant crown.

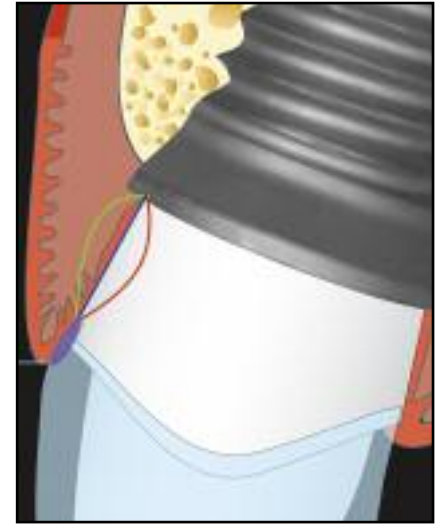
The following will describe how the seven variables of pink esthetic score, as defined by Fürhauser et al,<sup>12</sup> may be enhanced by modifying facial or interproximal critical or subcritical contour of the abutment-crown complex.

### *Gingival margin level*

The position of the gingival margin level determines the clinical crown length. The most facial point of the critical contour is essential in establishing the location of the gingival margin level and zenith position. As demonstrated in the natural dentition, the location of the facial gingival margin will vary depending on whether the tooth is moved lingually or facially



**Fig 1** Gingival margin position and architecture are determined by the implant abutment and crown contours. However, the soft tissue response differs depending on whether the contour alterations take place in a critical contour (blue) or subcritical contour (orange). While the critical contour plays a significant role in the support of the gingival margin (red), changes in the subcritical contour may not affect it significantly.

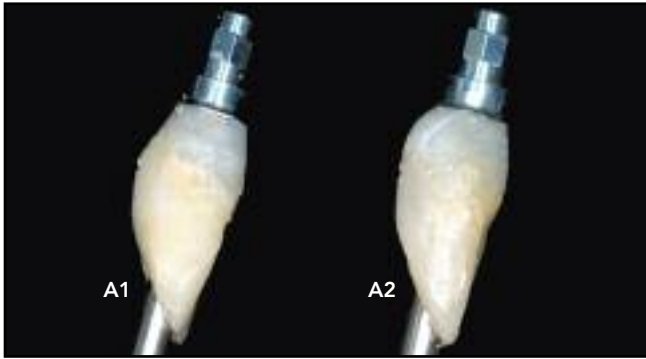

**Fig 2** The subcritical contour is located apical to the critical contour zone, provided there is sufficient running room, and may be shaped as a convex (green), flat (blue), or concave (red) surface. Subcritical contour modifications on the facial or interproximal aspects may influence the peri-implant tissues to some degree but will not affect the facial gingival margin level and crown form.

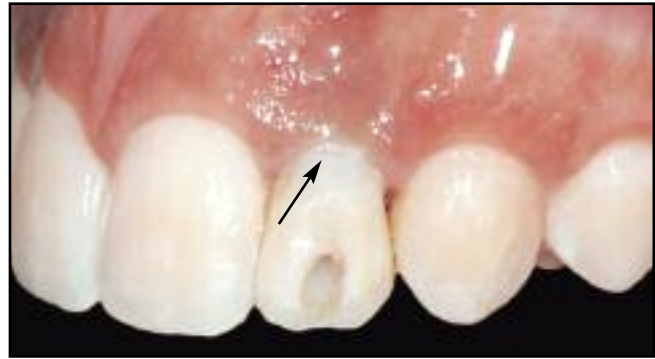or is rotated.<sup>13</sup> In the case of implants, when the critical contour moves facially, the gingival margin will migrate apically. On the other hand, when the critical contour is moved lingually, coronal migration of the gingival margin should be anticipated. Zenith position and the facial gingival architecture can be altered by changing the facial critical height of the contour mesially or distally. However, alteration of the sub-

critical contour within a certain physiologic range will not alter the gingival margin level significantly (Fig 3). Caution should be taken to avoid overcontouring the facial subcritical contour beyond the range of physiologic tolerance. Exaggerated subcritical convex contouring will induce gingival edema and possible sinus tract formation. Ultimately, gingival recession may occur.

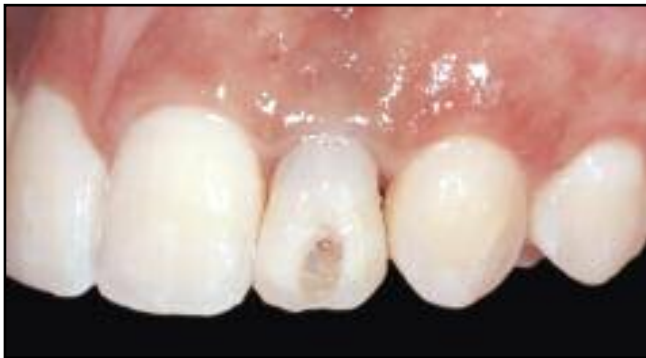**Fig 3** Clinical example of a facial subcritical contour modification.



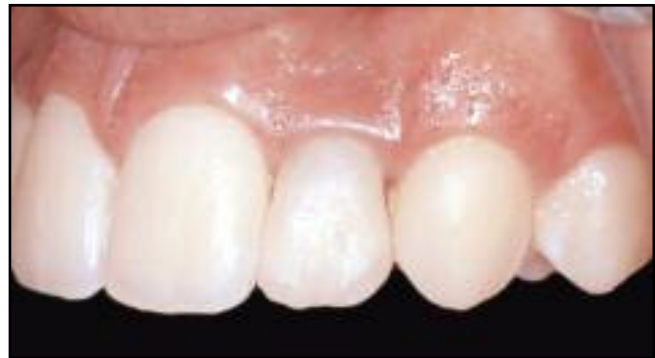**Fig 3a** (A1) A screw-retained provisional crown with an ideal facial critical contour and a flat subcritical contour. (A2) Facial subcritical contour modified to an “acceptable” convex contour with the maintained facial critical contour.



**Fig 3b** (A1) The peri-implant tissue profile was created with an ideal facial critical contour and a flat facial subcritical contour. A facial reference marking is noted 0.5 mm coronal to the facial gingival margin (arrow).



**Fig 3c** (A2) The peri-implant tissue response immediately after insertion with the provisional implant restoration, unaltered facial critical contour, and altered subcritical convex contour. Note some temporary blanching of the facial gingiva and a very slight apical positioning of the facial gingival margin.



**Fig 3d** Three-month follow-up evaluation. Some coronal migration of the facial gingival margin to the reference marking in Fig 3b can be noted. The total change of the facial gingival margin level is clinically insignificant.

### Interdental papillae

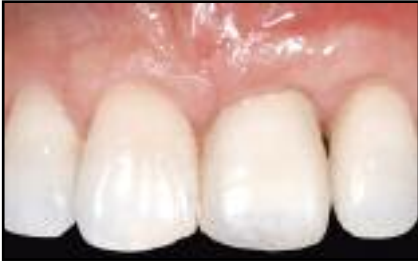The height of the interdental papillae between adjacent implants is determined by the underlying interimplant bony crest and possibly the remaining circular fibers. Papilla location between a natural tooth and an implant, however, is dependent on the level of the attachment apparatus of the adjacent tooth and the connective tissue that is attached to the natural tooth. Between the implant and tooth, a 4.5-mm average papillae height was reported.<sup>14,15</sup>

However, it has been stated that cramping the gingival embrasure by either lowering the contact point or narrowing its mesiodistal diameter will decrease the accessibility of the proximal surfaces and cause papillary overgrowth.<sup>6,8,11</sup> Under the same clinical conditions, increasing the convexity of the critical and subcritical contour may squeeze the interdental papillae, causing an increase in height of 0.5 to 1.0 mm, provided there is sufficient interdental space (2 to 3 mm). When the interproximal critical contour is altered,

the shape of the implant crown will become square. Modifying only the subcritical contour may achieve a similar outcome while preserving ideal crown form (Fig 4). Care must be taken to avoid impinging the adjacent alveolar bone while altering the interproximal subcritical contour.

The height of the papillae between adjacent implants has been reported to be approximately 3.4 mm from the crestal bone to the contact point.<sup>14,15</sup> Recently, platform switching has been shown to preserve the

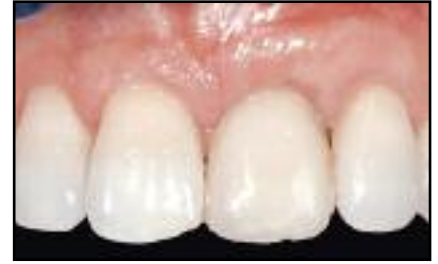**Fig 4** Clinical example of an interproximal subcritical contour modification.



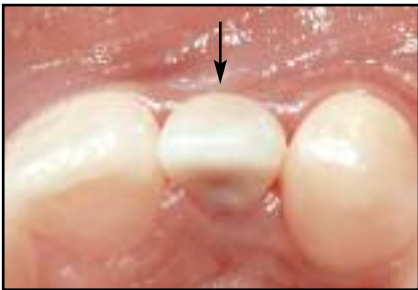**Fig 4a** Three-month postinsertion clinical photograph of an implant provisional crown at the maxillary left central incisor.



**Fig 4b** The distal interproximal subcritical contour was altered.

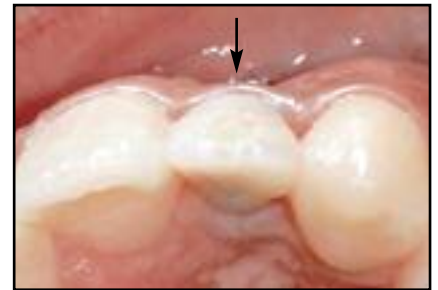

**Fig 4c** Two-month follow-up evaluation. Note the increased height of the interproximal papilla between the maxillary left incisors with reference to the mesial cemento-enamel junction level at the central incisor.



**Fig 5** Occlusal views of the case seen in Fig 3.

**Fig 5a** (left) A slightly deficient facial gingival profile can be seen at the maxillary left central incisor.



**Fig 5b** (right) An increased facial gingival profile was noted 3 months after alteration of the subcritical convex contour.

crestal bone between two implants.<sup>16-19</sup> Manipulating the critical and subcritical contours may further increase the papilla height between adjacent implants.

#### *Gingival architecture (gingival contour)*

The scallop of the gingival margin is determined mainly by the gingival level (zenith), the interdental papillae, and probably, most importantly, tooth form. Ideal facial critical contour can support a smooth, continuous gingival margin rather than an irregular or flat form.

#### *Alveolar process*

Correcting the appearance of a resorbed alveolar process requires adequate site preparation by means of ridge augmentation. This augmentation may comprise hard tissue, soft tissue, or a combination of both. However, minor defects may be addressed by overcontouring the facial subcritical contour within a physiologically acceptable range, providing support for the soft tissue without altering the gingival margin position (Figs 3 and 5).

### *Gingiva color*

Gingiva color is, of course, determined genetically. However, an ideal gingiva color must match that of the adjacent teeth, provided that they have the same tension. As in the natural dentition, it is thought that cervical curvatures function by holding the gingiva under definite tension.<sup>13</sup> In cases of immediate implant placement and provisionalization, loss of tissue volume may be expected as a result of the bone remodeling that occurs following tooth extraction.<sup>20</sup> As a result, dark shadows may develop around the facial gingival margin surrounding the implant, a result of a lack of support. A convex subcritical contour may enhance the appearance of a facial alveolar process and reduce shadow effects around the facial gingiva by supporting the facial gingival tissue. However, depending on the thickness of the facial gingiva, material selection for the definitive custom abutment may have a more significant influence in determining the color of the facial gingiva, particularly in cases where the soft tissues are thin.<sup>21,22</sup>

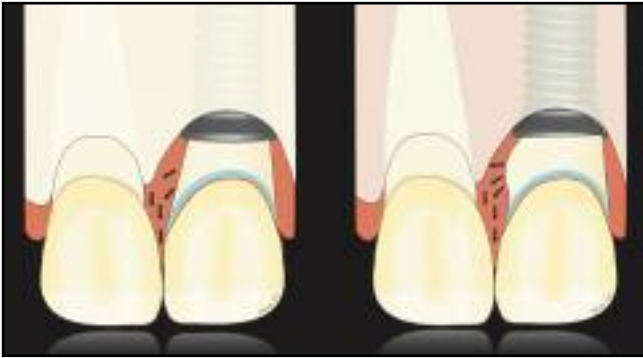
### *Gingiva texture*

Gingiva texture is the only factor that cannot be altered by changing the abutment and crown contour, both critical and subcritical. However, if the amount of facial critical or subcritical overcontour exceeds a physiologic range, soft tissue inflammation will occur.

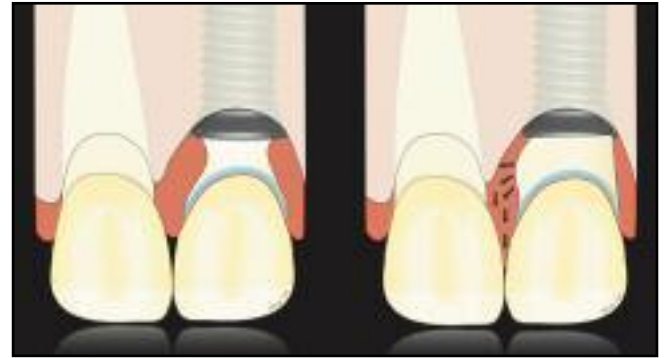
### **Discussion**

As demonstrated by Listgarten et al,<sup>23</sup> the implant supracrestal gingiva differs anatomically from that of the natural dentition, and they exhibit different physiologic behaviors as well. Overcontoured restorations on natural teeth may result in gingival inflammation or apical migration of the gingival margin. While overcontouring per se may not cause apical migration of the attachment apparatus, it may, however, result in a more apical position of the gingival margin. Conversely, changing the contour of implant-supported restorations will affect the position of the gingival margin. Changes limited to the subcritical contour will not alter the position of the gingival margin in a clinically significant manner, as demonstrated in this pilot study. The authors' experience seems to indicate that subcritical contour may be modified to enhance the soft tissue esthetics within a clinically acceptable range.

Amsterdam,<sup>24</sup> as early as 1974, stressed the importance of the shape of teeth and their impact on protecting the surrounding investing compartments of the periodontium. The effects of applying pressure on the interdental tissues by narrowing the embrasure have been demonstrated by several authors.<sup>6,8,11,25,26</sup> The reported changes comprised alterations of both critical and subcritical contours that generally resulted in square-shaped restorations. In situations where altered tooth forms are not desirable, however, similar soft tissue enhancements may be achieved by pressuring the tissue with a convex subcritical contour



**Fig 6** Modifying interproximal critical and subcritical contour (left) or modifying subcritical contour only (right) has a minor effect on papillae height.



**Fig 7** During the initial healing phase, a concave subcritical contour and an ideal critical contour should be provided to gain maximum tissue volume (left). Any modification of the subcritical contour to enhance peri-implant tissue should be performed with care since peri-implant tissue is healthy and mature (right).

(Fig 6). Especially in the “thin scalloped biotype,” where the adjacent teeth are triangular in shape with short contact and greater embrasure space, modifying the interproximal subcritical contour will increase the papilla height by 0.5 to 1.0 mm.

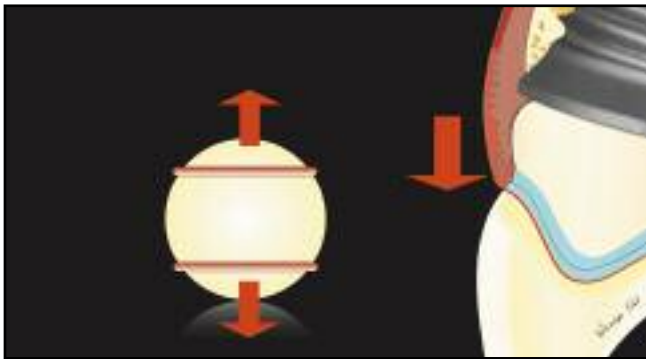
Clearly, adequate dimensions and volume of peri-implant soft tissue are required before the effect of any contour modifications can be observed. Although many variables may play a role in determining peri-implant soft tissue architecture, the periodontal biotype is the most influential.<sup>27</sup> In the case of a “thin scalloped biotype” where the teeth are predominantly triangular in shape, the characteristically

thin gingiva will preclude modifications to the facial subcritical contour. In terms of the facial gingival height, which is the distance from the implant level to the free gingival margin, the authors have observed that a facial gingival height of 3 mm is sufficient to allow adequate convex alterations of the facial subcritical contour without causing changes in the gingival margin level. Interproximally, the presence of a 2- to 3-mm-wide papilla is recommended prior to overcontouring the proximal critical or subcritical areas.

The timing to change the contour is very important as well. The timing of tissue maturation around implants, however, is not well documented.

Small and Tarnow<sup>28</sup> showed that the facial gingival margin stabilizes 3 months after abutment connection. It is recommended that any alteration of facial subcritical contour be performed once the gingival margin is stable. Rompen et al<sup>29</sup> showed that a concave transmucosal profile can minimize facial gingival recession. Accordingly, in situations where a minor soft tissue deficiency is present, the authors recommend using a concave subcritical contour during the initial healing phase to gain maximum tissue volume. Subsequent to gingival healing, the subcritical contour may be modified into a convex surface as necessary (Fig 7).





**Fig 8** The spherical concept. When an elastic is placed on the upper portion of a ball, the elastic will move up. On the other hand, placing an elastic on the lower portion of a ball will have the opposite effect. In a similar manner, when modifying a subcritical contour, the height of the contour is created apical to the gingival margin. Therefore, theoretically, pressure is placed on the gingival margin, positioning the gingival margin coronally.

Increasing the convexity of the subcritical contour presents some disadvantages. Maintenance procedures may be more difficult as a result of the limited access for instrumentation. An additional concern is the potential for future gingival recession. Rompen et al<sup>29</sup> demonstrated that a concave subcritical contour reduces facial gingival recession. One of the most interesting findings throughout this case series, however, was that within a physiologic range (yet to be defined), a convex subcritical contour will not induce facial gingival recession. Moreover, in many cases, coronal migration of the facial gingival margin may be observed (Fig 8). Also, the critical contour is dynamic depending on the position of the gingival margin. It will therefore migrate apically should recession occur. The exposed convex subcritical contour may then become the critical contour and potentially induce further recession. Should this be the case, removal of the restoration or abutment, followed by adjustment of critical and subcritical contours, is recommended. Additional studies with longer-term follow-up are necessary to determine the effects of altering

critical and subcritical contours around implant-supported restorations.

It is recommended that the peri-implant tissue be contoured with a provisional restoration prior to the fabrication of the definitive restoration, which then can duplicate the correctly shaped contour. Thereafter, a precisely duplicated definitive restoration can adequately support the peri-implant tissue and achieve a most predictable outcome. With advances in technology, abutment systems created with computer-aided design/computer-assisted manufacturing have become convenient tools. However, with the concept of implant abutment and crown contour in mind, one should adequately contour the peri-implant tissue with the provisional restoration and transfer the correctly contoured peri-implant tissue into the wax or acrylic resin pattern for scanning to produce the most predictable result. The authors, at this juncture, have not been able to develop the critical aspects of contour (as discussed in this paper) using certain computer-aided design/computer-assisted manufacturing technology on a consistent basis.

## Conclusions

Soft tissue esthetics around implant restorations may be enhanced through contour modifications of the abutment or implant-supported crown. The effects of these modifications vary depending on whether the contour alterations are applied on a critical contour or a subcritical contour because both have significant clinical implications. In cases where implant placement is ideal, altering critical and subcritical contour can optimize the clinical outcome by creating a better soft tissue profile. Further clinical studies are necessary to determine the limitation of the implant abutment and crown contour and long-term results should be evaluated.

## Acknowledgments

The authors would like to thank Drs Hsin-Fong (Julia) Liao, Miriam Habeeb, and Philip Fava for the editorial support.

## References

1. Davarpanah M, Martinez H, Tecucianu JF. Apical-coronal implant position: Recent surgical proposals. Technical note. *Int J Oral Maxillofac Implants* 2000;15:865–872.
2. Funato A, Salama MA, Ishikawa T, Garber DA, Salama H. Timing, positioning, and sequential staging in esthetic implant therapy: A four-dimensional perspective. *Int J Periodontics Restorative Dent* 2007;27:313–323.
3. Garber DA, Belser UC. Restoration-driven implant placement with restoration-generated site development. *Compend Contin Educ Dent* 1995;16:796, 798–802, 804.
4. Grunder U, Gracis S, Capelli M. Influence of the 3-D bone-to-implant relationship on esthetics. *Int J Periodontics Restorative Dent* 2005;25:113–119.
5. Kois JC. Predictable single tooth peri-implant esthetics: Five diagnostic keys. *Compend Contin Educ Dent* 2001;22:199–206.
6. Smukler H, Castellucci F, Capri D. The role of the implant housing in obtaining esthetics: Part 2. Customizing the peri-implant soft tissue. *Pract Proced Aesthet Dent* 2003;15:487–490.
7. Weisgold AS, Arnoux JP, Lu J. Single-tooth anterior implant: A world of caution. Part I. *J Esthet Dent* 1997;9:225–233.
8. Smukler H, Castellucci F, Capri D. The role of the implant housing in obtaining esthetics: Generation of peri-implant gingivae and papillae—Part 1. *Pract Proced Aesthet Dent* 2003;15:141–149.
9. Bichacho N, Landsberg CJ. Single implant restorations: Prosthetically induced soft tissue topography. *Pract Periodontics Aesthet Dent* 1997;9:745–752.
10. Lee EA. Transitional custom abutments: Optimizing aesthetic treatment in implant-supported restorations. *Pract Periodontics Aesthet Dent* 1999;11:1027–1034.
11. Morris ML. The position of the margin of the gingiva. *Oral Surg Oral Med Oral Pathol* 1958;11:969–984.
12. Fürhauser R, Florescu D, Benesch T, Haas R, Mailath G, Watzek G. Evaluation of soft tissue around single-tooth implant crowns: The pink esthetic score. *Clin Oral Implants Res* 2005;16:639–644.
13. Andlin-Sobocki A, Bodin L. Dimensional alterations of the gingiva related to changes of facial/lingual tooth position in permanent anterior teeth of children. A 2-year longitudinal study. *J Clin Periodontol* 1993;20:219–224.
14. Tarnow D, Elian N, Fletcher P, et al. Vertical distance from the crest of bone to the height of the interproximal papilla between adjacent implants. *J Periodontol* 2003;74:1785–1788.
15. Salama H, Salama MA, Garber D, Adar P. The interproximal height of bone: A guidepost to predictable aesthetic strategies and soft tissue contours in anterior tooth replacement. *Pract Periodontics Aesthet Dent* 1998;10:1131–1141.
16. Baumgarten H, Cocchetto R, Testori T, Meltzer A, Porter S. A new implant design for crestal bone preservation: Initial observations and case report. *Pract Proced Aesthet Dent* 2005;17:735–740.
17. Cappiello M, Luongo R, Di Iorio D, Bugea C, Cocchetto R, Celletti R. Evaluation of peri-implant bone loss around platform-switched implants. *Int J Periodontics Restorative Dent* 2008;28:347–355.
18. Hürzeler M, Fickl S, Zuhr O, Wachtel HC. Peri-implant bone level around implants with platform-switched abutments: Preliminary data from a prospective study. *J Oral Maxillofac Surg* 2007;65(7 suppl 1):33–39 [erratum 2008;66:2195–2196].
19. Rodriguez-Ciurana X, Vela-Nebot X, Segalá-Torres M, et al. The effect of inter-implant distance on the height of the inter-implant bone crest when using platform-switched implants. *Int J Periodontics Restorative Dent* 2009;29:141–151.
20. Araújo MG, Sukekava F, Wennström JL, Lindhe J. Ridge alterations following implant placement in fresh extraction sockets: An experimental study in the dog. *J Clin Periodontol* 2005;32:645–652.
21. Jung RE, Holderegger C, Sailer I, Khraisat A, Suter A, Hämmerle CH. The effect of all-ceramic and porcelain-fused-to-metal restorations on marginal peri-implant soft tissue color: A randomized controlled clinical trial. *Int J Periodontics Restorative Dent* 2008;28:357–365.
22. Jung RE, Sailer I, Hämmerle CH, Attin T, Schmidlin P. In vitro color changes of soft tissues caused by restorative materials. *Int J Periodontics Restorative Dent* 2007;27:251–257.
23. Listgarten MA, Lang NP, Schroeder HE, Schroeder A. Periodontal tissues and their counterparts around endosseous implants [corrected and republished with original paging, article originally printed in *Clin Oral Implants Res* 1991 Jan-Mar;2(1):1–19]. *Clin Oral Implants Research* 1991;2(3):1–19.
24. Amsterdam M. Periodontal prosthesis. Twenty-five years in retrospect. *Alpha Omegan* 1974;67:8–52.
25. Bichacho N. Papilla regeneration by non-invasive prosthodontic treatment: Segmental proximal restorations. *Pract Periodontics Aesthet Dent* 1998;10:75, 77–78.
26. Kokich VG. Esthetics: The orthodontic-periodontic restorative connection. *Semin Orthod* 1996;2:21–30.
27. Weisgold AS. Contours of the full crown restoration. *Alpha Omegan* 1977;70:77–89.
28. Small PN, Tarnow DP. Gingival recession around implants: A 1-year longitudinal prospective study. *Int J Oral Maxillofac Implants* 2000;15:527–532.
29. Rompen E, Raepsaet N, Domken O, Touati B, Van Dooren E. Soft tissue stability at the facial aspect of gingivally converging abutments in the esthetic zone: A pilot clinical study. *J Prosthet Dent* 2007;97(suppl):S119–S125.